



A. J. Still

Still Technique for the Busy Office

Richard L Van Buskirk, DO, PhD, FAAO

Still Technique

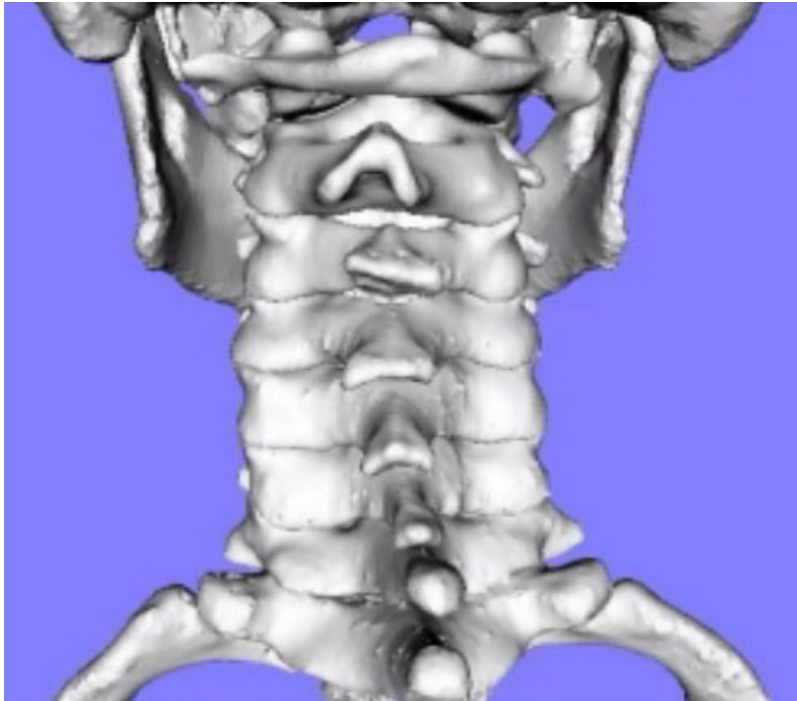- Modern Still Technique is a redeveloped manipulative method based on technology first used by Andrew Taylor Still, MD.
- It was reintroduced in 1996:
 - Richard L. Van Buskirk, DO, PhD, A manipulative technique of Andrew Taylor Still, JAOA, 1996, pp. 597-602.

Still Technique: The Method

- Place the affected tissue in its position of ease.
- Introduce a **force vector** of less than 1 pound through the affected tissue. The force vector can be from another part of the body (long lever) or directly over the affected tissue (short lever).
- Move the affected tissue in a smooth path from its position of ease toward and through the position of its restriction.
- As the tissue moves through its restriction a “bump” and/or a click may be felt or heard. Neither is necessary for correction of the somatic dysfunction.
- Passively move the patient back to neutral and retest.

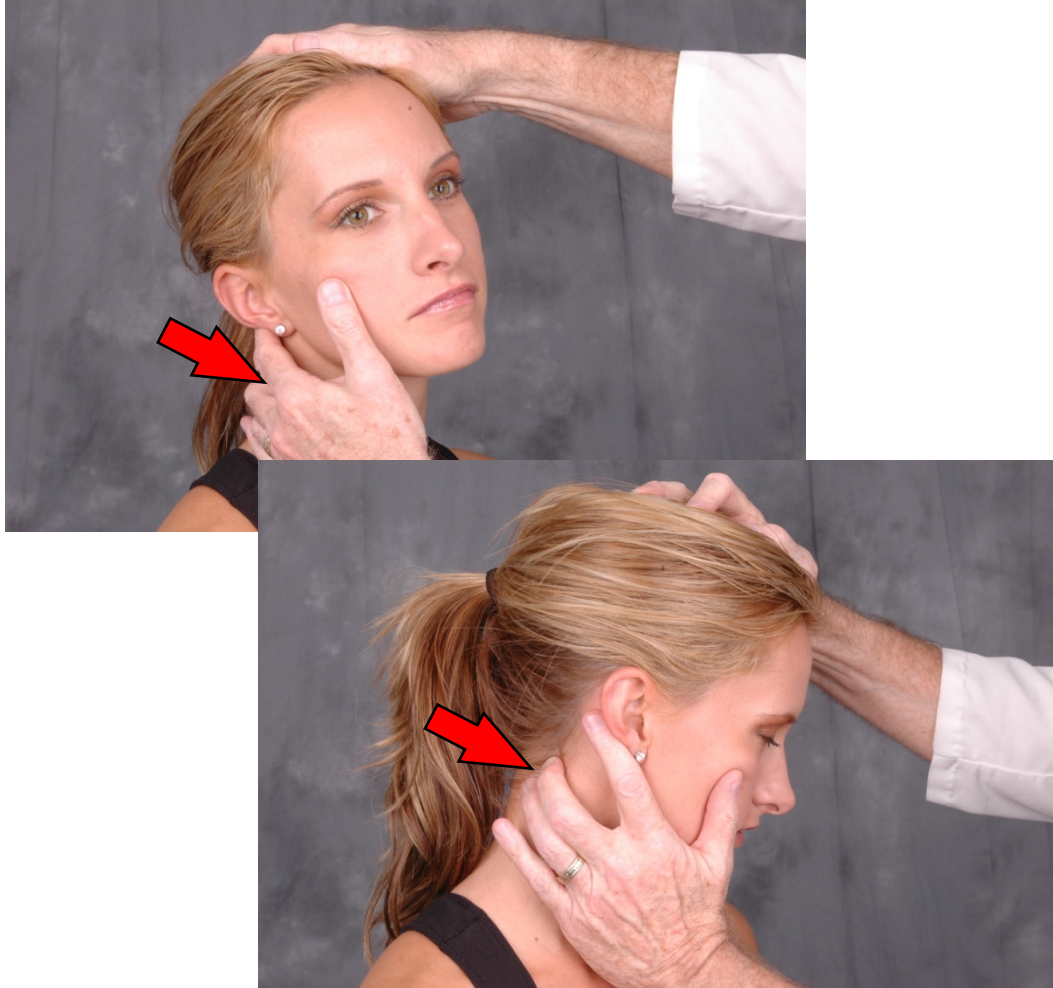- In this brief course we will focus on using short lever techniques with the patient seated. It will allow you to develop manipulative techniques you can use every day in your patient contacts in the office.

Typical Cervical Spine, Diagnosis



- Palpate the posterior lateral prominence of the **articular pillar** of each segment. Prominence and tenderness on one side indicates the segment is sidebent & rotated toward that side.
- Evaluate the segment by flexing and extending the spine down to the segment. The segment's position of ease is demonstrated when its' articular pillar prominence disappears.

Extended Cervical Dysfunction

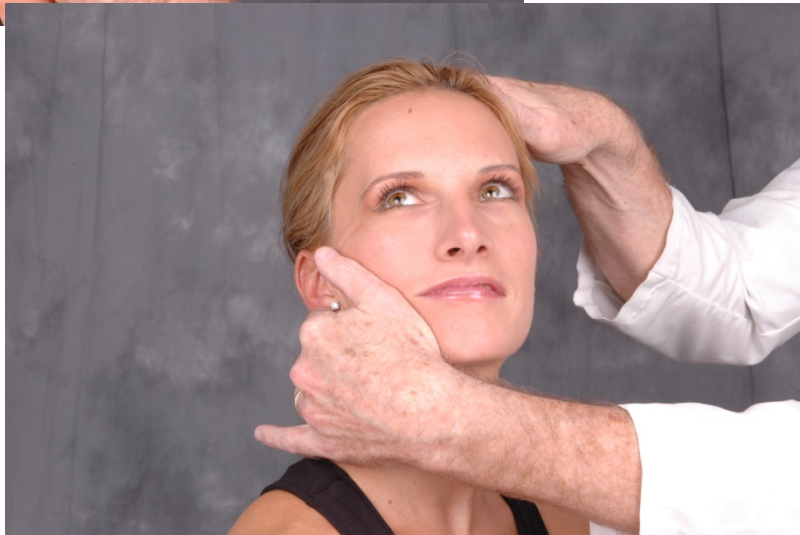
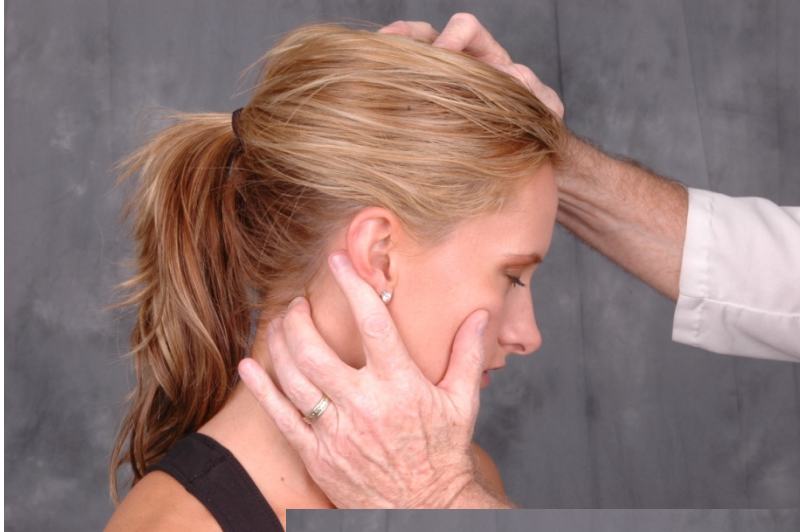
1. Stand in front of the patient with a finger on the articular pillar of the affected segment.
2. Your operating hand is on the patient's head.
3. The patient's head and neck are extended, sidebent, & rotated toward the ease.
4. Using your operating hand, introduce the force vector toward the affected segment.
5. Rotate the head and neck through neutral into left sidebending and rotation and flexion.
6. As the segment passes the original barrier you may feel release.
7. Release compression, return the head and neck to neutral and retest.

Flexed Cervical Dysfunction, Diagnosis

- For a **flexed** cervical segment the ease is in flexion with sidebending and rotation to the same side. Its restriction is in extension with sidebending and rotation to the opposite side.

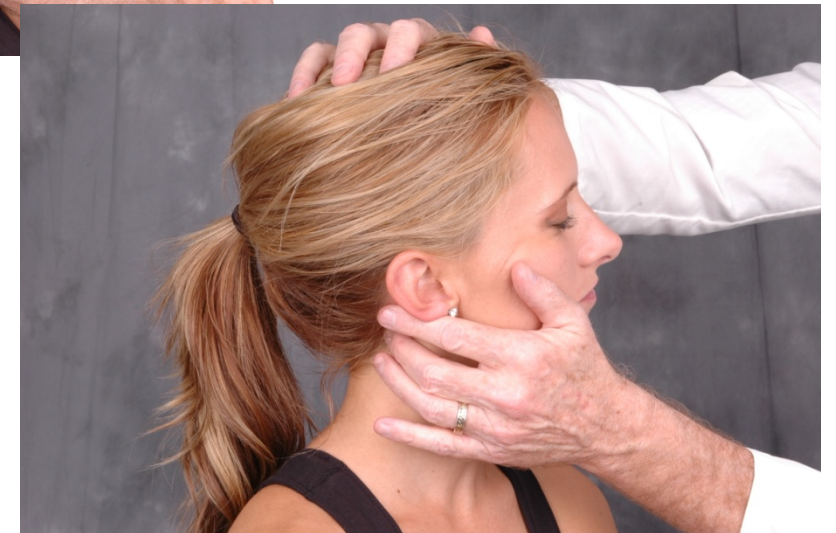Flexed Cervical Dysfunction



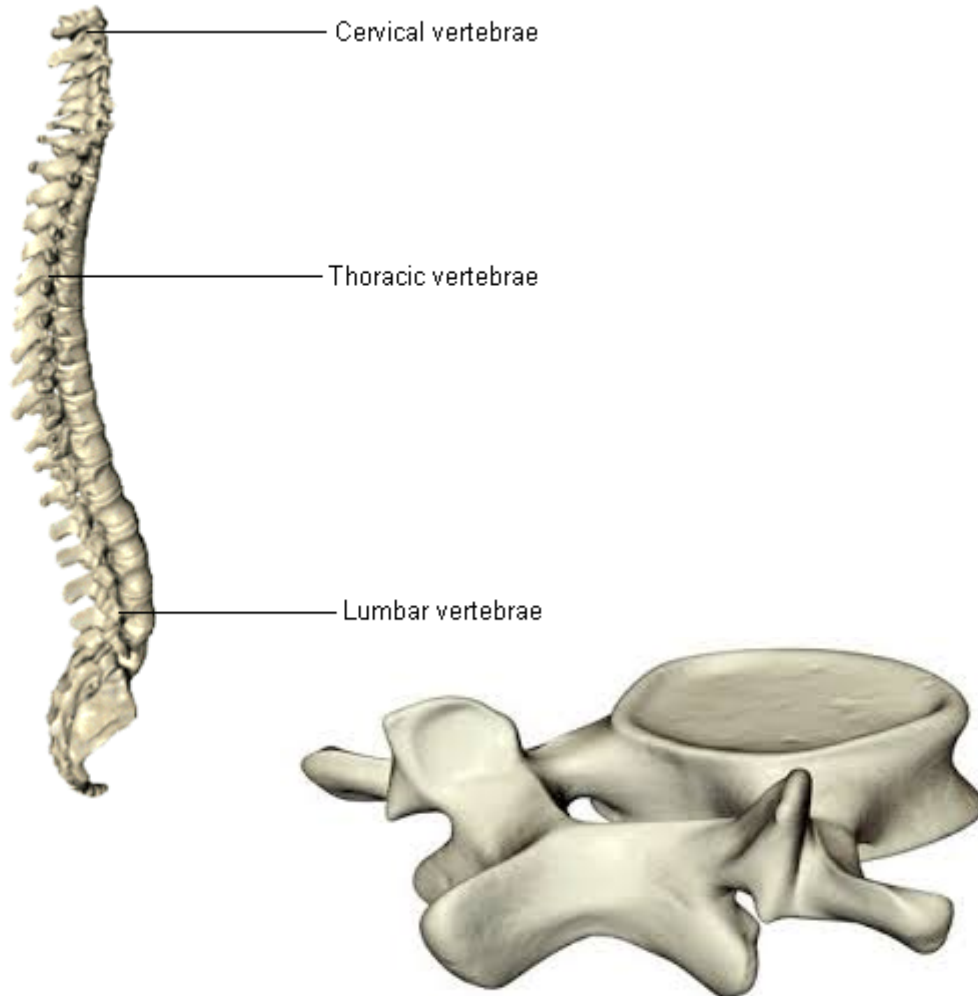
1. Treatment of a flexed cervical dysfunction starts similar to the extended except the head and neck are flexed, sidebent and rotated toward the side of ease (left in this case).
2. Introduce the force vector onto the affected segment.
3. The operating hand rotates the patient's head and neck through neutral into right extension, sidebending and rotation.
4. As the segment passes the original barrier you may feel release.
5. Release compression, return the head and neck to neutral. Retest.

Neutral Cervical Spine Dysfunctions

1. Your sensing fingertip is on the neutral segment's articular pillar.
2. Your operating hand is on the top of the head.
3. Set the patient's neck so the segment is at ease (sidebent left, rotated right in this case).
4. Introduce compression to the segment.
5. Maintain compression. Carry the head and neck through the restriction (right sidebending, left rotation).
6. Release compression. Return to neutral. Retest.



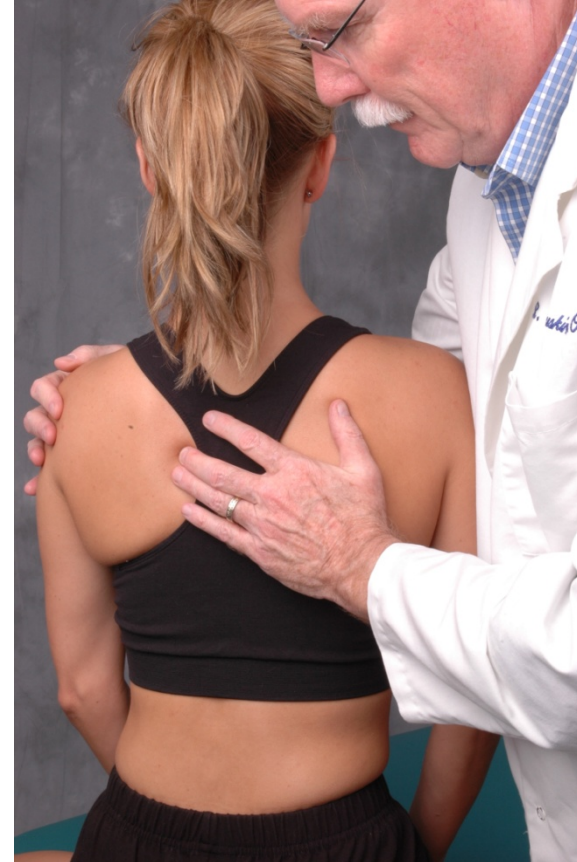
Thoracic and lumbar spine, anatomy



- There are 12 ***thoracic vertebrae*** and 5 ***lumbar vertebrae***. Like the lower cervical vertebrae the thoracic and lumbar vertebrae consist of an anterior body, resting on a disc and a posterior neural arch with transverse processes, superior and inferior articular processes (facets) and a posterior spinous process.
- The thoracic vertebrae are distinguished by having ribs attached.

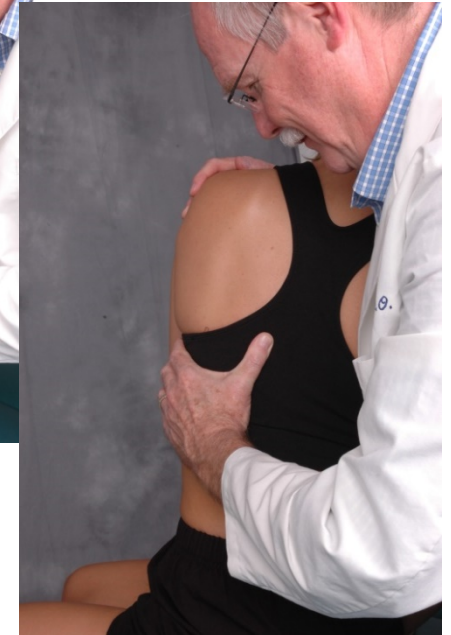
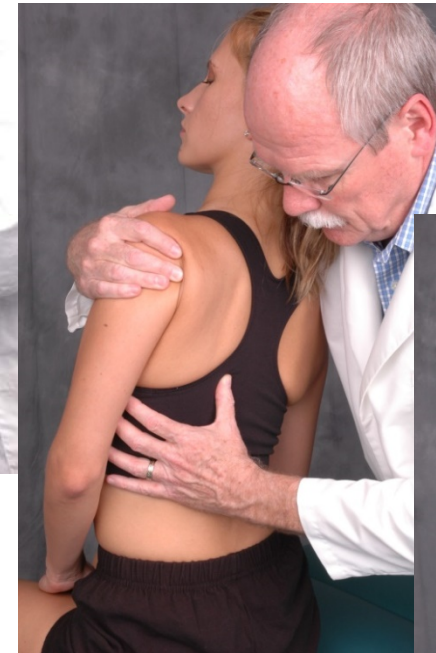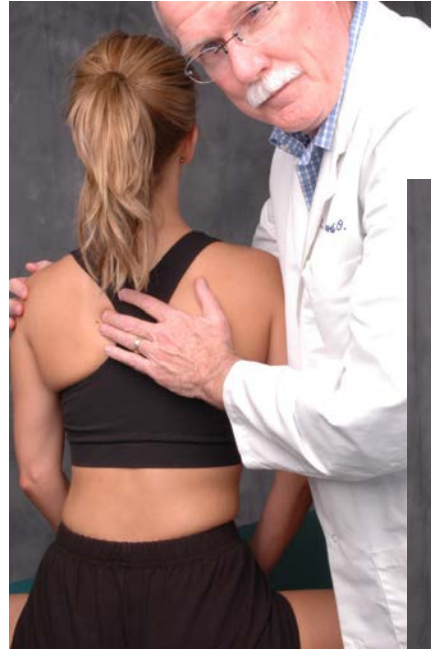
Thoracic Type II Dysfunctions, Diagnosis

- Check the relative position of the transverse processes. The overlying tissues of a posterior rotated transverse process are prominent, boggy & tender. The segment is rotated & sidebent toward this side.
- Induce flexion & extension from above. The prominent transverse process softens in either flexion or extension defining the position of ease & the somatic dysfunction.



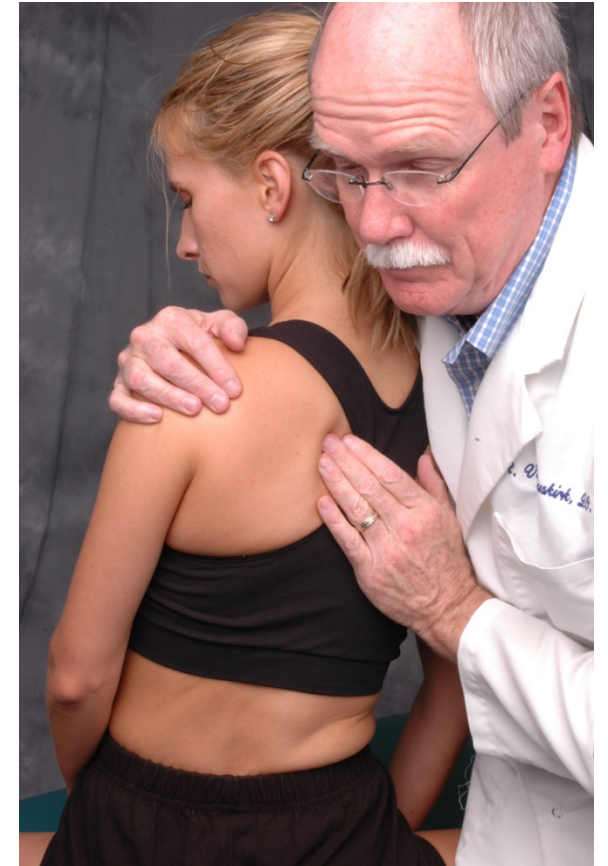
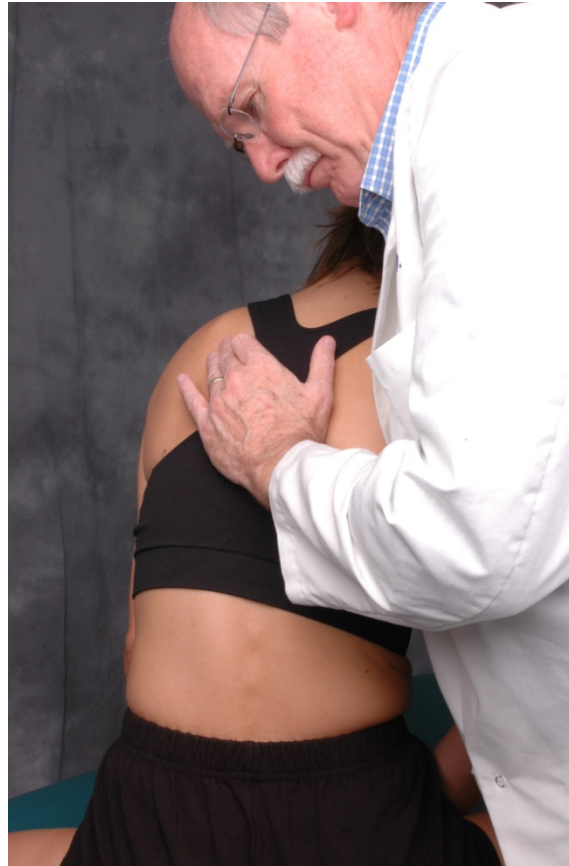Extended Thoracic Type II Dysfunctions

1. Place a sensing finger on the transverse process of the affected segment.
2. Pass your operating arm over the patient's shoulder and around the superior chest wall so your operating hand is on the patient's shoulder.
3. Extend, sidebend and rotate the patient's spine toward the side of ease, producing palpable relaxation.
5. Introduce compression to the transverse process.
6. Simultaneously reduce extension and rotate the spine through neutral into flexion and sidebending toward the side of restriction.
7. Once release is noted remove compression and passively return the patient to neutral. Retest



Flexed Thoracic Type II Dysfunctions

Flexed somatic dysfunctions are treated similarly except they start with the segment flexed sidebent and rotated towards the side of ease and finish extended, sidebent and rotated to the side of restriction,



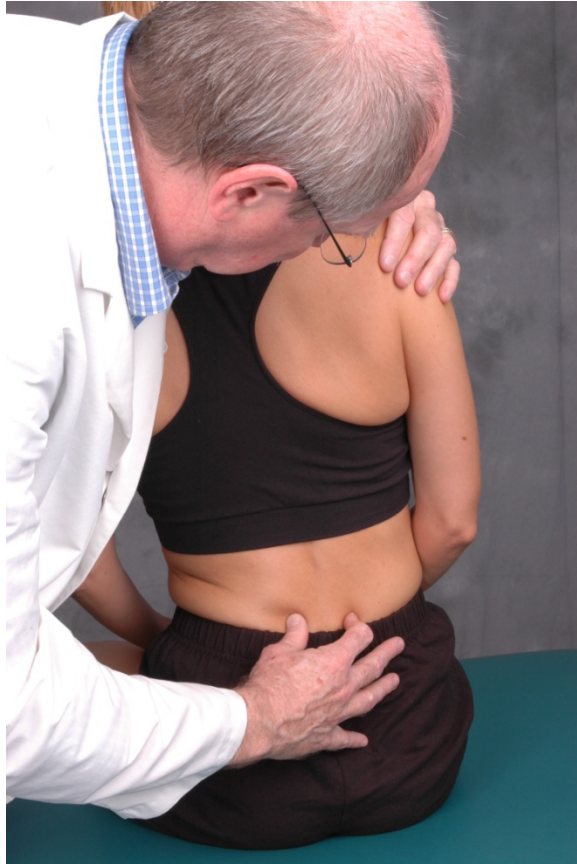T1 Neutral Dysfunction

- **Diagnosis & Treatment:** One of the most common thoracic Type I somatic dysfunctions is at T1. To treat this use the head and neck as if you were performing a treatment on the neck.

Neutral Lumbar Segment Dysfunction, Diagnosis

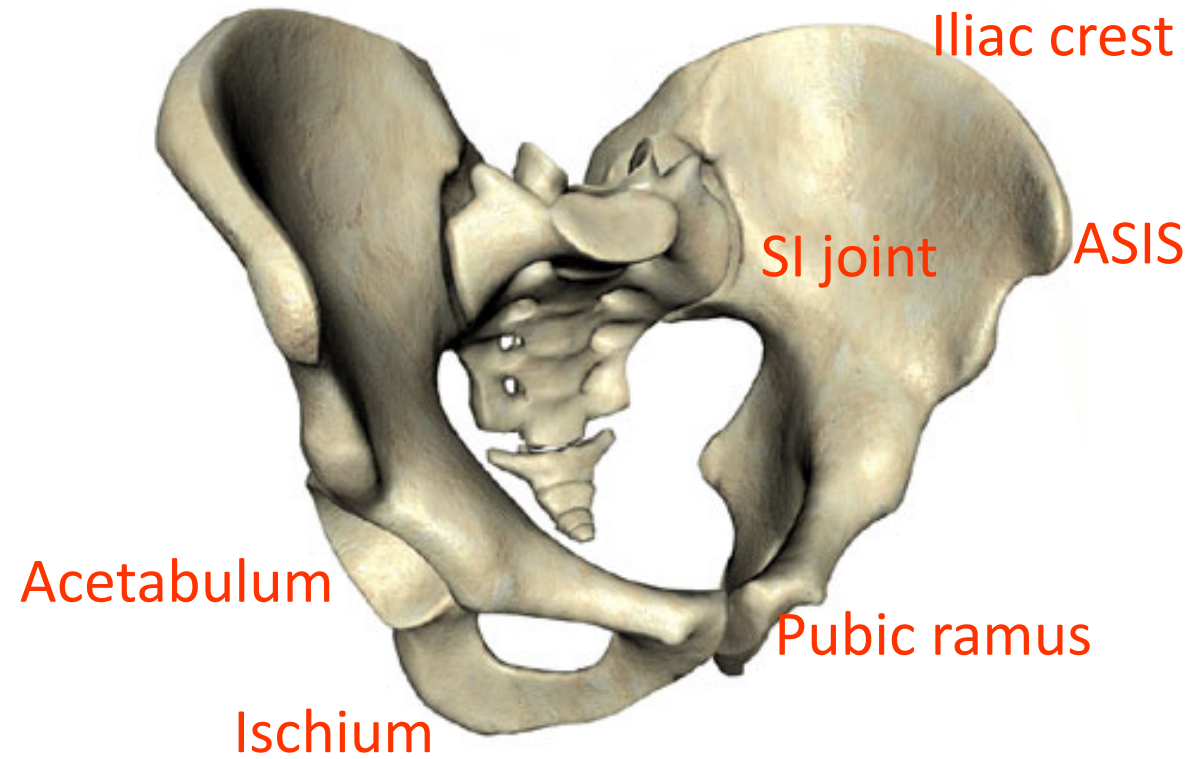
- The most common thoracic or lumbar single segment Type I involves L5 on S1. Often these are of traumatic origin.

Neutral Lumbar Segment Dysfunction



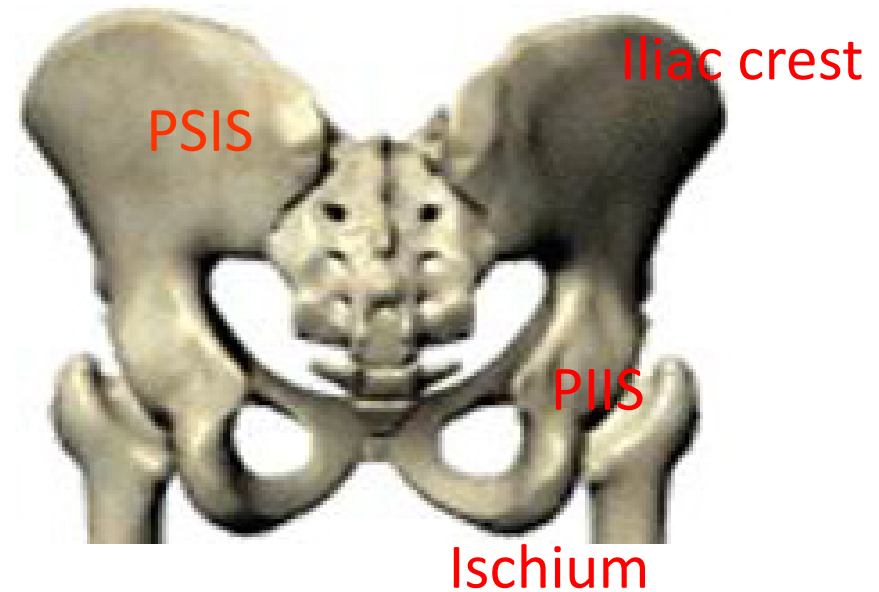
1. Use the patient and physician positions for a thoracic vertebra.
2. Sidebend the patient's spine toward the left side (in this case) and rotate it toward the right side, producing relaxation.
3. Introduce compression to the transverse process.
5. Simultaneously sidebend the spine toward the right side and it rotate toward the left side.
6. Once release is noted remove compression and passively return the patient to neutral. Retest.

Innominates



Innominates

- Posteriorly parallel to the sacroiliac joints is a posterior protuberance, the ***Posterior Superior Iliac Spine*** (PSIS). Below that is an inferiorly oriented projection, the ***Posterior Inferior Iliac Spine*** (PIIS).

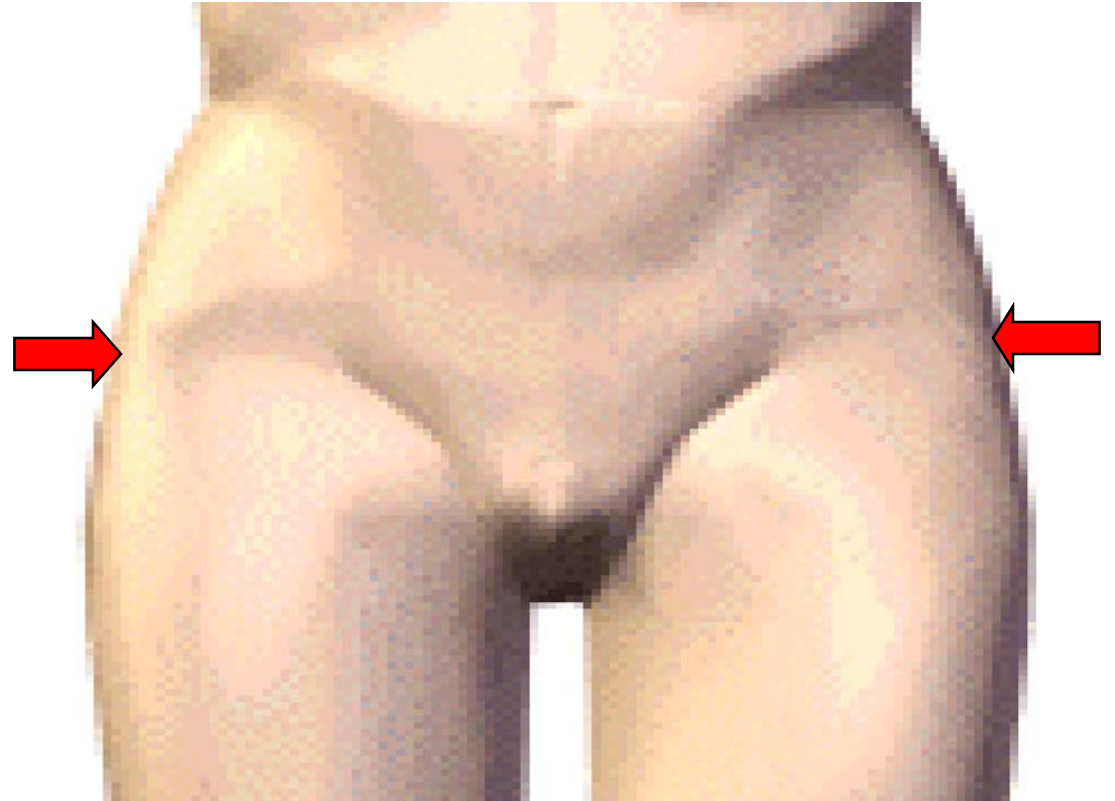


Innominate Dysfunctions, Diagnosis

- Determining which half of the pelvis is restricted and the type of restriction involves three or four operations.
 - Standing flexion test (not commonly used by Van Buskirk).
 - A pelvic translation test with the patient supine.
 - The relative position of the Anterior Superior Iliac Spine (ASIS).
 - The relative position of the Posterior Superior Iliac Spine (PSIS).

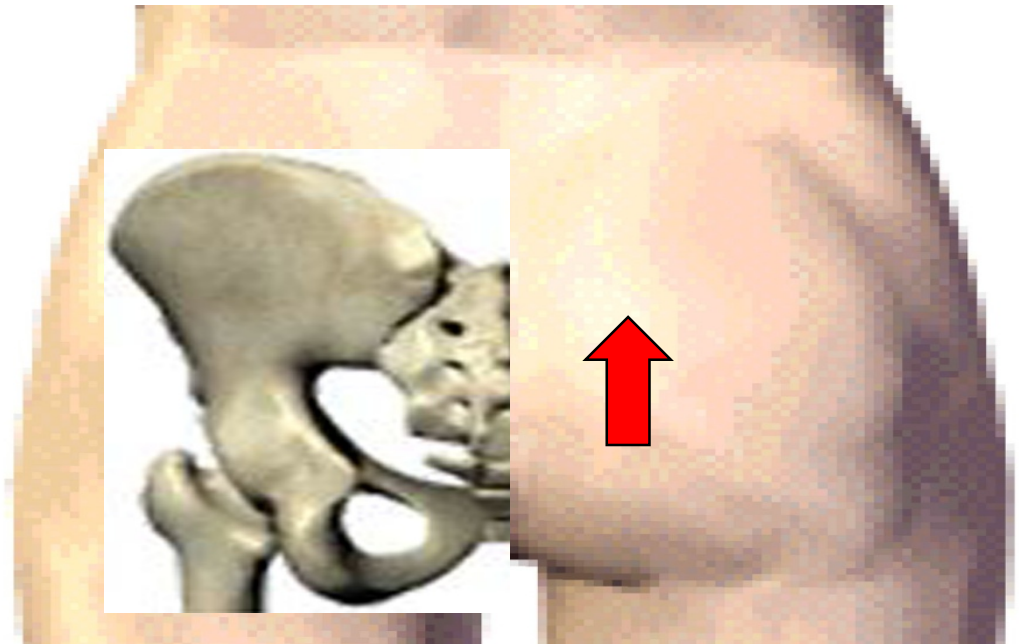
Innominate Dysfunctions, Diagnosis

- Perform a **pelvic translation** test by placing fingers lateral to both ASIS. Compression is performed from one side and then the other. The side towards which motion is restricted is positive.



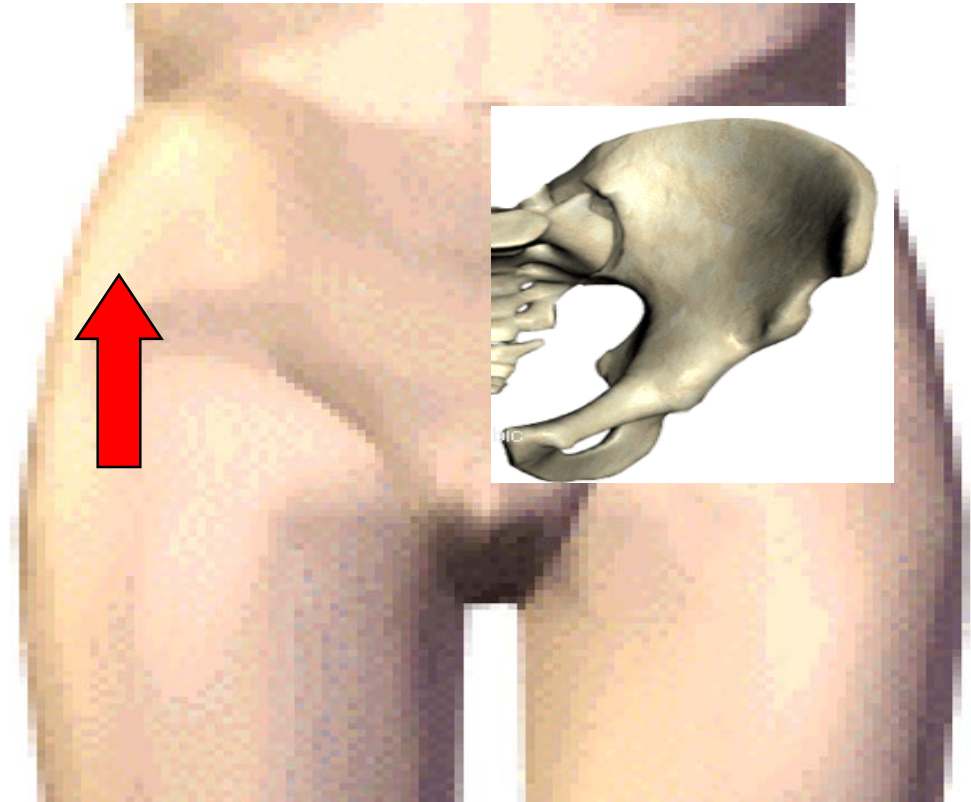
Innominate Dysfunctions, Diagnosis

- Determine the relative position of the **PSIS** with the patient seated. To do this sweep your thumbs upward about 3 cm from midline. When you hit the inferior margins of the boney prominence, note which is superior.



Innominate Dysfunctions, Diagnosis

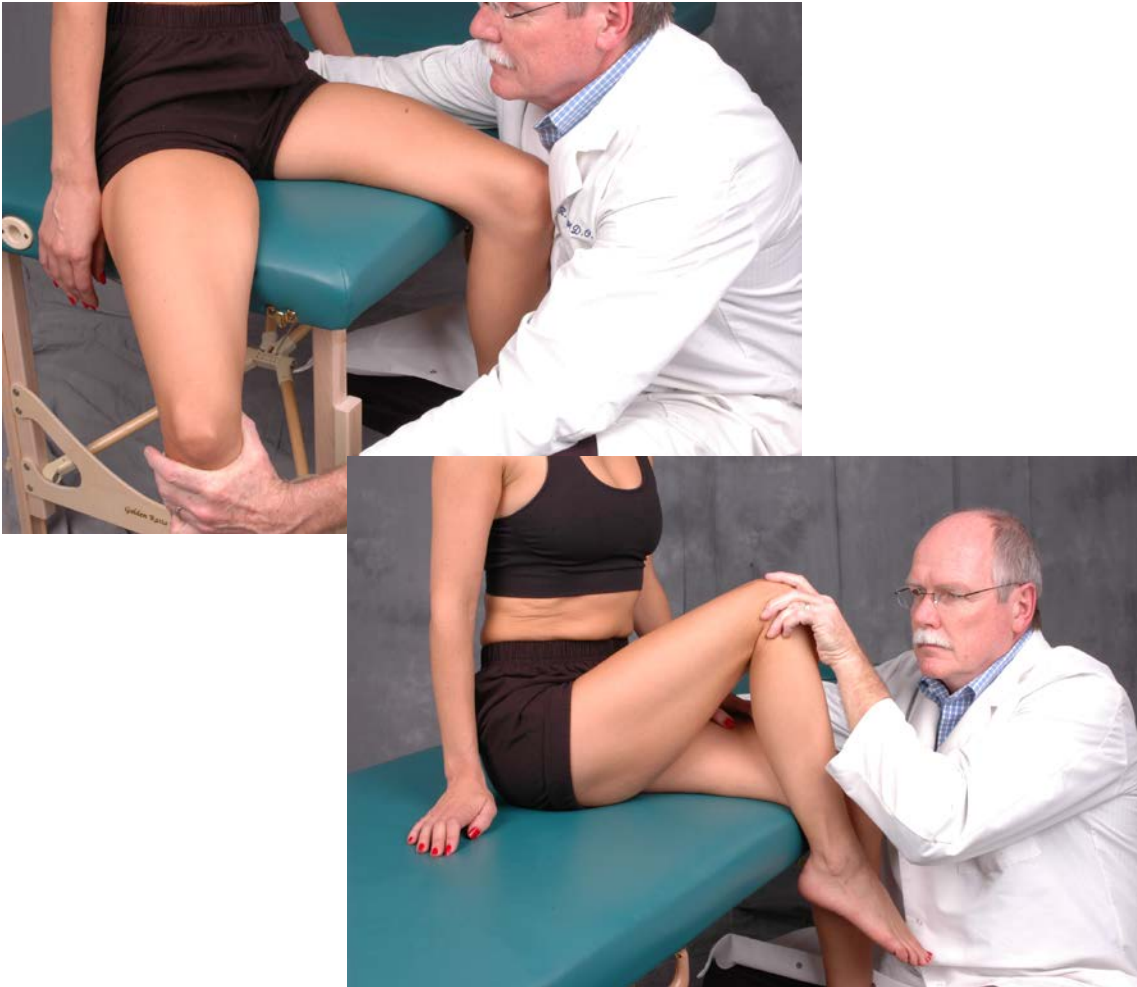- Determine relative position of the **ASIS**. Bring your thumbs up from the upper anterior lateral thighs until you contact the inferior boney prominence of the ASIS. Note which is more superior.



Anterior and Posterior Innominate, Diagnosis

- For an anterior innominate dysfunction the
 - Standing flexion test is positive on that side.
 - Pelvic translation will not move the pelvis toward that side.
 - The PSIS is superior on that side.
 - The ASIS is inferior on that side.
- For a posterior innominate dysfunction the
 - Standing flexion test is positive on that side.
 - Pelvic translation will not move the pelvis toward that side.
 - The PSIS is inferior on that side.
 - The ASIS is superior on that side.

Anterior Innominate



1. The patient sits on the end at the edge 40 degree. The knee is flexed.
2. Stand at the patient's side.
3. Monitor and produce a compression vector at the sacroiliac joint.
4. Capture the knee with your other hand and lift it forward, bringing the hip into flexion and slight adduction.
5. Once release is felt at the SI joint return the hip to straight position and retest.

Posterior Innominate

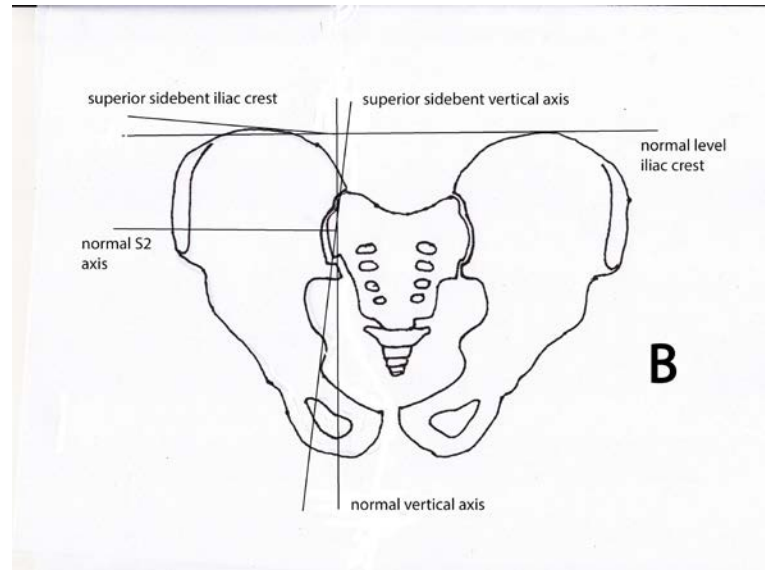
To treat a posterior innominate with the patient seated:

1. The patient sits on the end of the table with the affected hip at the edge. The thigh is adducted over the normal thigh.
2. Stand in front of the patient towards the side of the restriction.
3. Monitor and compress the affected SI joint.
4. Lift the affected leg and bring it into abduction and then extend the hip.
5. Release compression at the SI joint and restore the leg to normal sitting position and retest.

Superior Sheared Innominate, Diagnosis

- For a superior sheared (upslipped) innominate dysfunction
 - Standing flexion test is positive on that side.
 - Pelvic translation will not move the pelvis toward that side.
 - The PSIS is superior on that side.
 - The ASIS is superior on that side.
 - Generally an upslipped innominate is accompanied by a short leg on the same side.

Superior Sheared Innominate



- Over the past 7 years we have been rethinking the concept of a superior sheared innominate.
- Frequently the shortening of the leg on the superior sheared side is between $3/8$ and $3/4$ inch (6 to 15 mm).
- Rather than shearing we have proposed that the innominate is sidebent at the SI joint.

Superior Sheared Innominate

1. The patient is seated on the table. You stand behind the patient with your arm over the patient's shoulder similar to treating the spine.
2. Sidebend the patient toward the sheared innominate.
3. Use your knee to introduce a compression vector to the SI joint on that side. Alternately you can have the patient compress the SI joint with their finger.
4. Your other hand is on the iliac crest of the superior sheared innominate.
5. Simultaneously press down on the iliac crest and sidebend the patient toward the other side.
6. Restore to neutral and retest.